

**Obstetrics and Gynecology: in
2 volumes. Volume 2.
Gynecology: textbook**

КУПИТИ

Improvement of the quality of training the students of higher medical education establishments is connected with the improvement of forms and methods of teaching subjects, as well as the introduction of the latest achievements of modern forms, learning the high standard and control of the level of knowledge.

■ The materials presented in this textbook are based on the program of studying the subject “Obstetrics and Gynecology” on the position of evidence-based medicine and the transition to the Bologna Process. ■ Each unit contains test tasks and clinical cases with answers to check up the students’ know-ledge. ■ At the end of each subunit there is the list of practical skills that the students should master. ■ For students of higher medical education establishments.

OBSTETRICS & GYNECOLOGY

IN TWO VOLUMES

TEXTBOOK

Edited by
Academician of the NAS of Ukraine,
Professor V.I. Gryshchenko,
Professor M.O. Shcherbina

Volume 2

Gynecology

THIRD EDITION

ALLOWED

by the Ministry of Health of Ukraine
as a textbook for students of higher medical
education establishments

PUBLISHED

in accordance with the Order of the Ministry
of Health of Ukraine No. 502 of 22 June 2010
as a textbook for students of higher medical
education establishments

KYIV

AUS MEDICINE PUBLISHING
2022

UDC 618.1
LBC 48.76;57.1ya73
G19

*Allowed by the Ministry of Health of Ukraine as a textbook for students
of higher medical education establishments*

*Published in accordance with the Order of the Ministry of Health of Ukraine
No. 502 of 22 June 2010 as a textbook for students of higher medical
education establishments*

Authors:

V.I. Gryshchenko — Academic of the National Academy of Sciences of Ukraine (NASU);
M.O. Shcherbina — Professor;
B.M. Ventskiivskyi — Corresponding Member of the National Academy of Medical Sciences
of Ukraine (NAMSU);
V.V. Kaminskyi — Corresponding Member of the NAMSU;
L.B. Markin — Corresponding Member of the NAMSU;
L.V. Potapova — Professor;
V.V. Lazurenko — Professor;
O.V. Mertsalova — Professor;
O.P. Lipko — Professor;
I.M. Shcherbina — Professor;
M.G. Gryshchenko — Professor

Reviewers:

A.M. Gromova — Doctor of Medicine, Professor, Head of the Department of Obstetrics and
Gynecology No. 1 of Ukrainian Medical Stomatological Academy;
V.V. Shcherbakova — Doctor of Medicine, Professor

Obstetrics and Gynecology : in 2 vol. : textbook. Vol. 2. Gynecology / V.I. Gryshchenko, M.O. Shcherbina, B.M. Ventskiivskyi et al. ; edited by V.I. Gryshchenko, M.O. Shcherbina. — 3rd edition. — K. : AUS Medicine Publishing, 2022. — 352 p. + 8 color insets.

ISBN 978-617-505-900-5

Improvement of the quality of training the students of higher medical education establishments is connected with the improvement of forms and methods of teaching subjects, as well as the introduction of the latest achievements of modern forms, learning the high standard and control of the level of knowledge.

The materials presented in this textbook are based on the program of studying the subject “Obstetrics and Gynecology” on the position of evidence-based medicine and the transition to the Bologna Process.

Each unit contains test tasks and clinical cases with answers to check up the students’ knowledge. At the end of each subunit there is the list of practical skills that the students should master. For students of higher medical education establishments.

UDC 618.1
LBC 48.76;57.1ya73

ISBN 978-617-505-900-5

© V.I. Gryshchenko, M.O. Shcherbina, B.M. Ventskiivskyi,
V.V. Kaminskyi, L.B. Markin, L.V. Potapova,
V.V. Lazurenko, O.V. Mertsalova, O.P. Lipko,
I.M. Shcherbina, M.G. Gryshchenko, 2014, 2022
© AUS Medicine Publishing, design, 2022

CHAPTER 10

Maldevelopments of Female Genitalia and Pubescence Disorders

Maldevelopments of the genital organs are congenital violations of the anatomical structure in the form of incomplete organogenesis, violations of sizes, forms, proportions, symmetry, topography, and also the presence of formations unusual to the woman's organism in the postnatal period.

The frequency of anomalies of the development of the genital organs makes 1 % of cases. Lately there is the tendency to their increasing. Maldevelopments not only lead to disorders of the reproductive function, but also cause a loss of life quality.

ETIOLOGY AND PATHOGENESIS

Among the reasons for the maldevelopments of the genital organs they distinguish the *endogenous, exogenous, hereditary and multifactors*. Maldevelopments are formed in the process of embryogenesis under the influence of harmful factors, which disturb it.

The diseases of the mother (infectious, endocrine), intoxication (alcohol, narcotic and chemical substances), radiation, complications of the pregnancy and delivery belong to these factors. An important role plays the hereditary factors: the chromosomal and gene mutations (chromosome aberration, mosaicism, pericentric inversion of chromosomes etc.) and also the exogenous factors (stress situations, psychologic traumatic experiences and long-term starvation).

The pathogenesis is connected with the disorders of the fusion of paramesonephral ducts, their recanalisation; defects of the formation of the urogenital sinus, and also pathology of the gonad organogenesis, which depends on the peculiarities of the development of the median kidney, and migration of gonocytes into the embryonal gonad anlage in time (Fig. 35).

In 50 % of cases the genital organ malformation is combined with other anomalies, mainly with the urinary system deformities; that are conditioned by the unity of the embryonal anlagen; and also the musculoskeletal system, the digestive tract (anus adhesion), heart, organs of hearing and vision and the endometrium.

Terminology

Characterizing the different types of anomalies of the genital organs, they use the following terms: the absence of an organ is *agenesia*; the absence of a part of the organ is *aplasia*; the underdevelopment of the organ is *atresia*; the violation of patency, blockage, adhesion of some part of the female genitals is *gynatresia*; the defect of the organ is *hypoplasia*; the absence of adhesion or occlusion of a part of the organ is *dysraphia*; increase of the quantity of a part of the organ is *multiplication*; the abnormal displacement or absence of the body tissue, the organ or a part of it is *heterotopy or ectopy*.

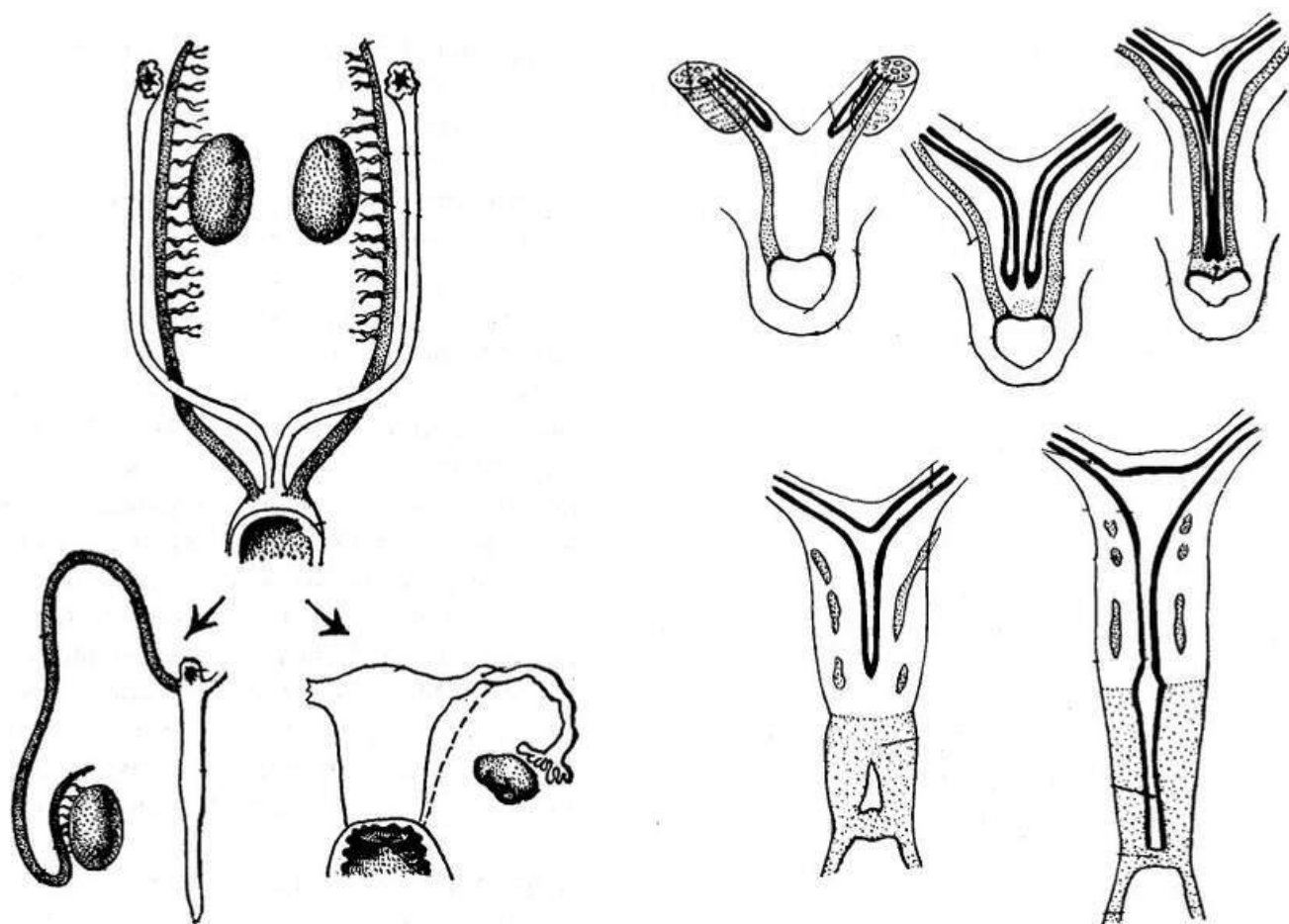


Fig. 35. Organogenesis of gonads

HYMEN AND VULVAL MALDEVELOPMENTS

Under conditions of the normal development of genitals the hymen has an opening or openings for the outflow of the menstrual blood. Atresia of the hymen is one of the most widespread manifestations of the vulval maldevelopments.

The pathology is shown up in the pubescence. During menstruation the blood gradually fills the vagina, uterus and uterine tubes (Fig. 36). The blood doesn't get into the abdominal cavity due to obliterated pili of the fallopian tubes.

Clinical presentation

The clinical presentation is characterized by the periodic pain in the lower abdomen in missing of menstruations (pseudoamenorrhea). Quite often there is a danger of infecting the gathered blood. During the observation of the external genital organs diverticulum of the hymen of dark blue-crimson color is well visible; there is no opening in it.

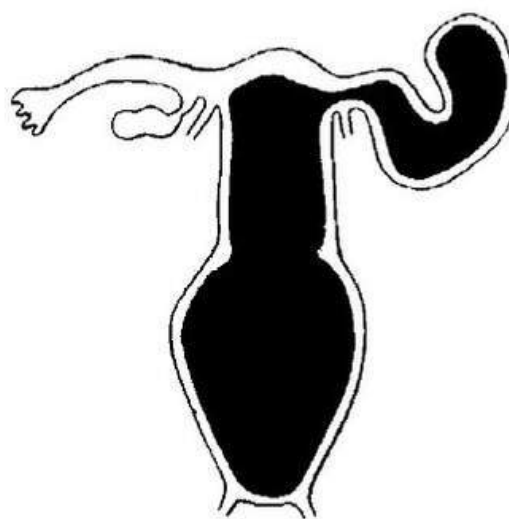


Fig. 36. Hematocolpos, hematometra, hematosalpinx in the atresia of the hymen

Chapter 10

In the rectoabdominal inspections of the patient they expose the tumular formation of elastic consistency in the area of the vagina; on the top of this formation there is a small dense body (uterus). If it is difficult to make the diagnosis, they use the ultrasonic research. The surgical treatment of this defect consists of providing the outflow of the gathered menstrual blood by the method of the cruciform section of the hymen. The edges of cutting are sewn by the knotted catgut sutures.

EXTERNAL GENITALS MALDEVELOPMENTS

To the most widespread maldevelopment of the external genital organs they include the *hermaphroditism* and *congenital adrenogenital syndrome*.

The hermaphroditism (bisexual) is the presence in one person both the male and female sexual glands. The true hermaphrodites are the persons with two functioning glands of both sexual representatives (the phenomenon is very rare) or the persons with elements of the ovary and the testicle combined in one sexual gland (*ovotestis*). The pseudohermaphrodite (pseudohermaphroditism) is the person who has the sexual glands of one sex and the external genital organs and the secondary sexual signs of the opposite sex.

According to the extraordinary structure of the sexual glands, they distinguish the pseudohermaphroditism of the male and female type. In the male pseudohermaphroditism the sexual gland is male, but the structure of the external genital organs is close to the female structure. In the female pseudohermaphroditism the internal genital organs (the ovaries, uterus, vagina) are formed correctly; the clitoris is enlarged, it reminds the penis, and the large pudendal lips acquire the form of the scrotum and so on.

The female pseudohermaphroditism develops on a background of the congenital adrenogenital syndrome, and also because of taking the androgens or progesterone in high doses during the pregnancy. Beside the glucocorticoid therapy the patients are indicated the surgical correction: the amputation of the clitoris; the dissection of the urogenital sinus.

The female pseudohermaphroditism can appear on a background of the virilizing tumors of the adrenal glands and the ovaries. The surgical treatment consists of the tumor eradication.

The practical interest is also caused by deformations of the external genital organs, caused by the hypospadias or epispadias, ectopia into the vagina or into the lumen of the rectum. In this case the fecal masses of the new-born girl are excreted through the vagina in connection with the imperforation of the rectum. This state appears, when the premature stopping of development of the urogenital fold; as a rule it separates the cloaca on the 7th week of the development of the embryo; and later it is transformed into the perineum.

VAGINAL MALDEVELOPMENTS

The vaginal maldevelopments can be separated or combined with the uterine maldevelopments. Variability of the vaginal maldevelopments is related to its forming from different embryonic germs: its upper thirds is formed from the paramesonephral canals, which were accreted; and two lower thirds are formed from the urogenital sinus. The vaginal maldevelopments are presented by atresiae, agenésiae and aplasiae.

Atresia of the vagina is the complete or partial closure of the vagina in upper, middle or lower parts. The anomaly arises up on a background of the formed paramesonephral canals, which did not meet with the exodermal urogenital sinus.

Among the clinical signs of the vaginal atresia there is the periodic pain in the lower abdomen and absence of menstruation. The blood is accumulated higher of the area of imperforation, gradually filling the uterine cavity. The hematometra is formed.

The diagnosis and the level of imperforation are made by the methods of the rectal and ultrasonic research and sounding of the vagina.

The treatment is operative: in the imperforation of the lower thirds of the vagina they stratify tissues in the area of its entrance; dissect the inferior fornix of the vagina and suture the mucous membrane to the entrance into it.

If the imperforation is localized in the middle thirds of the vagina, they dissect the tissues between its upper and lower thirds, and then suture the mucous membrane of these areas together.

In the imperforation of the upper thirds of the vagina, if there are no the vaginal vaults and location of the cervix in the cellulose of the small pelvis, the operative intervention gives the least effect. The operation is effective, if it is possibly to empty the hematometra through the cervical canal, and then sewing it to the inferior vault of the vagina.

Sometimes the vagina has the septa. The longitudinal vaginal septa are formed as a result of incomplete confluence of the paramesonephral canals. The septa arrived the entrance into the vagina are combined with the uterine maldevelopment (doubling of the uterus). In some cases there is imperforation of one side of the vagina and menarche, which is accompanied by development of hematocolpos and hematometra, requiring the surgical dissection or resection of the septum. They dissect the septum in that case, if it hinders the normal sexual life or the maternity process.

The transversal septa of the vagina arise up on a background of incomplete confluence of the paramesonephral canals with the urogenital sinus. Such septa can be complete or incomplete, circular or sickle-like, localized in inferior or middle portions of the vagina.

The high septa may be diagnosed by mistake as the vaginal aplasia. The low located septa are similar to atresia of the hymen. The septum has to be removed to the appearance of menarche because of the danger of development of the hematocolpos and hematometra.

The complete absence of the vagina (agenesia) is a consequence of absence or uncompleted development of the paramesonephral canals.

The vaginal agenesia is mainly observed in the patients with Rokitansky-Kuster's syndrome; such women after the chromosomal set have the rudimentary germ of the uterus, hypoplastic uterine tubes and normal ovaries.

The vaginal aplasia is the primary absence of the vagina, predefined by stopping of formation of the vaginal tube canalization on the definite stage.

The clinical presentation is characterized by amenorrhea and impossibility to normal sexual life. A diagnosis is made on the basis of data of anamnesis and the results of the gynecological examination. For additional methods they can apply the laparoscopy, computer or MRT. The treatment is surgical. The time to make the operation is determined individually. For the patients with presence of the functioning uterus (in order to preserve fertility) the operation is made by coming of the menarche. If there is no uterus, the operation is made for the formation of the vagina (for the sexual function).

Chapter 10

The colpopoiesis is the creation of an artificial vagina (from the Greek word 'colpos' means 'vagina' and the word 'poiesis' means 'to create'). There are few methods of creation of an artificial vagina: from the simple breaking up of the rectum-bladder space to application of the auto- and heterotransplants. The first operation concerning the absence of the vagina was made in 1810 by G. Dupuytren; he formed the entrance between the urinary bladder and the rectum. However the similar operations were unsuccessful in connection with the scarring and complete obliteration of the created canal. With the purpose to prevent the development of complications, they began to use autotransplants (pieces of skins, taken from the patient's thigh (Crede, I.I. Hryshchenko). But the transplantation of the free shred of the skin (by Tirsch), using the prostheses and frameworks, has certain defects, such as necrosis and tearing away of the skin shred, or hair growth on it. Attempts of epithelisation of the vagina by heterotransplants (wall of serosal cystoma of the ovary, fetal membranes (I.D. Arist)) were unsuccessful. The colpopoiesis using the intestinal tube was offered for the first time by V.F. Snegirev (1892), who took the distal segment of the rectum; D. Baldwin (1904) used the small intestine; M.S. Alexandrov (1932) and E.E. Gigovsky (1949) worked out in detail the methods of the colpopoiesis using the sigmoid intestine. However these operations had many complications; and that is why they hadn't purchased the wide usage.

The first attempt to use the pelvic peritoneum as the plastic material was made by D.O. Ott, later this method was applied by M.I. Csido, I.D. Arist, C.G. Davidov and V.I. Hryshchenko.

This operation is made by three stages.

The first stage is the forming of the canal between the urinary bladder and the rectum.

In the second stage they made laparotomy, at which they sew the center of the uterine rudiment and take it ahead. In the area of the rectal-uterine cavity in transversal direction they cut the peritoneum. On the anterior, posterior and lateral areas of the peritoneum the surgeon applies four catgut ligatures, swiging for which the assistant places the peritoneum to the entrance of the vagina. The edges of the peritoneum are sutured to the mucous membrane of the vaginal opening.

The third stage consists of the creation of the vaginal vault. For this purpose they use the uterine rudiment with the club-shaped bodies, peritoneum of ligamentous apparatus and the anterior surface of the rectum.

It's possible to use one-staged colpopoiesis: the pelvic peritoneum by the perineum the surgeon pulls down and sews to the entrance of the vagina. The vault of the vagina is formed from the uterine rudiment. An operation requires a great experience and a high skill of the surgeon.

It is known another ways of colpopoiesis:

- the ulvovaginoplastic by Williams;
- the colpopoiesis with the use of tissues of the small pudendal lips;
- covering the vagina with the alloplastic materials (kapron, lavsan nets and so on).

If there are contra-indications for the surgical treatment, they apply the Franco's dilation method; the bloodless method of colpopoiesis, offered by B.F. Sherstnyov.

There is the executed gradual distortion of the vaginal vestibulum to achievement of the desirable result by the usage of the special colpoelongator.

UTERINE MALDEVELOPMENT

The frequency of the congenital maldevelopments of the uterus arrives 15 %. They are reason of sterileness, algodysmenorrhea, spontaneous abortions, premature labor, malposition of the fetus, discoordination of the labor activity, post-partum bleeding, ectopic pregnancy and many others.

The maldevelopment of the uterus arise up because of violation of the process of confluence, wrong forming or incomplete canalisation of the paramesonephral ducts. In the case of their unconfluence along the all length there are two uteri, two cervixes and two vaginae (*uterus didelphus*) (Fig. 37).

Here the both sexual organs are divided by the transversal fold of the peritoneum, on both sides there is one ovary and one uterine tube. Both uteri are well functioning and pregnancy in them can be one after another.

Sometimes there is a presence of two uteri and two vaginae, united together on certain areas (*uterus duplex and vagina duplex*) (Fig. 38).

One of the uteri is quite often differ in size and functions than another; so it is possible the imperforation of the hymen or the internal ostium.

The two-horned uterus is the consequence of unconfluence of those parts of paramesonephral canals, due to which a single uterus appears usually, thus the vagina is general. The most expressed variant of the two-horned uterus is *the uterus bicornis bicollis* (Fig. 39), that shows up the split of the cervix and the uterine body.

The divided body of the uterus with the single cervix is named *the uterus bicornis unicollis* (Fig. 40); and it is formed as a result of confluence of the paramesonephral canals in the area of the cervix.

Less expressed variants of the two-horned uterus are the saddle-shaped and arched uterus (*uterus arcuatus*), the uterus with the complete or incomplete partition (*uterus septus, subseptus*).

If the paramesonephral canals were not angered and haven't lumina, both uteri acquire the type of two rudimentary horns of solid structure (*uterus bicornis rudimentarius solidus*) or Rokitansky-Kustner's syndrome (Fig. 41).

Uterus unicornis is very rare pathology, which arises up on a background of the ateliosis of one of the paramesonephral canals (Fig. 42). The pathology, as a rule, shows up the presence of only one kidney and one ovary. Because of considerable exclamation of

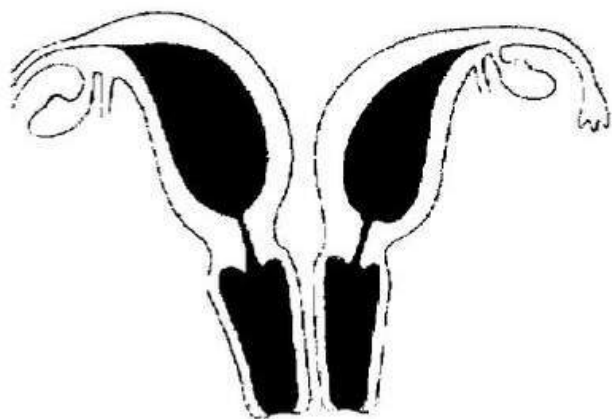


Fig. 37. Uterus didelphus

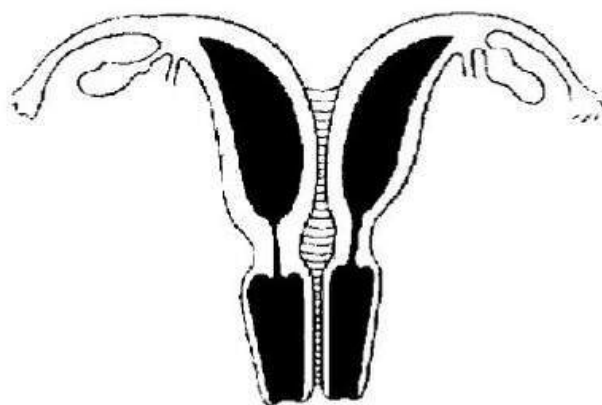


Fig. 38. Uterus duplex et vagina duplex

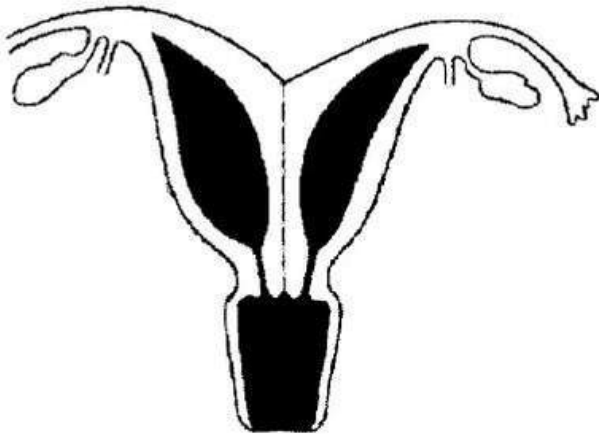


Fig. 39. Uterus bicornis bicolis

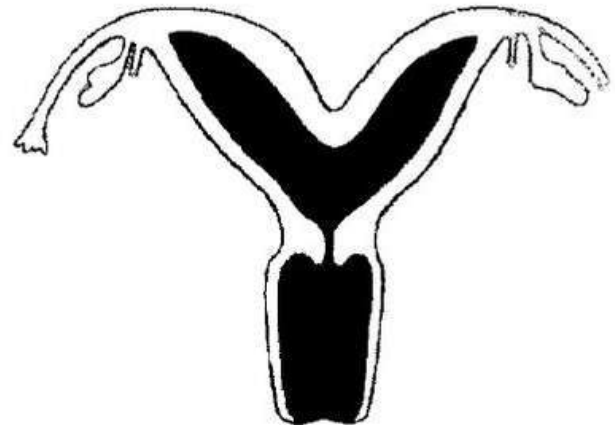


Fig. 40. Uterus bicornis unicolis

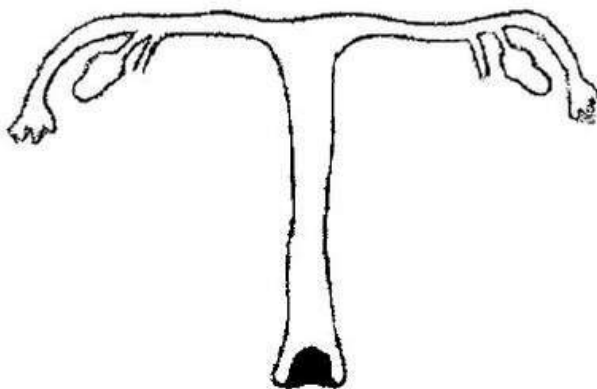


Fig. 41. Uterus bicornis rudimentarius solidus

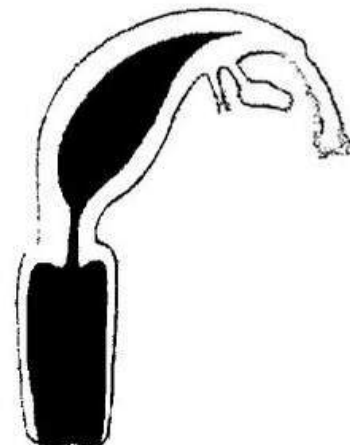

Fig. 42. Uterus unicornis

one of the paramesonephral canals *the uterus unicornis with a rudimentary horn* is formed (Fig. 43).

Depending on the state of the rudimentary horn they distinguish the unicornous uterus with the unfunctioning rudimentary organ of the second horn and the unicornous uterus with the functioning rudimentary horn. If a rudimentary horn has a cavity, then it is very important to find out, whether it is related to the uterine cavity. The presence of the functioning rudimentary horn is accompanied by such complications as polymenorrhea, algodysmenorrhea and ectopic pregnancy.

They distinguish the imperforation of the cervix, at which the uterine body is connected with the vagina only by a thin tissue bundle, fully deprived the lumen. The congenital imperforation of the uterine cavity is the extraordinarily rare pathology, mainly of acquired character; it develops after the rough curettage or cauterization of the endometrium.

Clinical presentation

The maldevelopments of the uterus are characterized by violations of the menstrual function such as amenorrhea or polymenorrhea. The primary amenorrhea is the most frequent sign of maldevelopments of the genital organs. In many cases there is pseudo-amenorrhea related to impossibility of outflow of the menstrual blood as a result of imperforation or aplasia in any area of the genital organs, located lower than the internal ostium. Considerably rarer they expose the secondary amenorrhea. Another symptom is the ab-

dominal pain, which appears in the pubertal period and increases monthly, sometimes accompanied by fainting. During palpation of the abdomen there is a tumular formation of considerable sizes, located in its lower part (hematometra). The peritoneal phenomena can arise up on a background of infecting of hematometra or in the case of getting the menstrual blood into the abdominal cavity, which is the characteristic for the long-term existent imperforation.

Diagnostics

Sometimes it is difficult to diagnose the uterine maldevelopment. It is based on data of anamnesis, clinical signs, results of the detailed gynecological examination of the patient and additional methods of research, which are enable to set the form of maldevelopment not only of the genital, but also the urinary organs. Observation of the vagina in specula, probing of the vagina and the uterus are enabling to educe the doubling of the cervix, the septum in the uterus and some other maldevelopments. Using the bimanual and rectal research they diagnose the doubling of the uterus, set the presence of the rudimentary horn and hematometra as the large elastic painless tumor. Sometimes the dystopic kidney can be determined in the small pelvis. The hysterosalpingographia is indicated for suspicion on the two-horned uterus, presence of septa in it, and also the rudimentary horn, if its lumen is related to the uterine cavity.

The ultrasonic research, nuclear magnetically-resonance and computer tomography have an important diagnostic value at all types of maldevelopments of the sexual internal organs. Besides the endoscopic methods of research they also apply the hysteroscopy and laparoscopy. Taking into account the frequency of combination of maldevelopments of the genital and urinary organs they made the excretory urography in every case of maldevelopments of the genital organs.

Treatment

It isn't needed to treat the patients in different forms of doubling of the uterus and the vagina, if they are not accompanied by violation of outflow of the menstrual blood. In the case of delay of outflow of the menstrual blood the surgical treatment is shown with the maximal carving of the septum of the serried vagina and removal of the functional horn of the uterus. The surgical treatment in the case of the two-horned uterus and the presence of the septum in its cavity is conducted by indications (involuntary abortions). The septum of the uterus can be divided during the hysteroscopy by section it with scissors or laser, resectoscope or electro-needle under the laparoscopic control for avoidance the perforation of the uterus. The hysteroscopic approach is more popular than abdominal metroplasty, as it is less traumatic interference, which will assist the conduct of delivery without application of the Cesarean section. At the two-horned uterus they use the abdominal access, and the metroplasty is performed in three stages: the first — opening of the uterine cavity and cutting of the septum; the second — taking measures, which prevent development of the endometrial adhesions, they drainage the uterine cavity; the third — they suture the cut on the uterus. The existed methods are differing only by means of type of opening of the uterus.

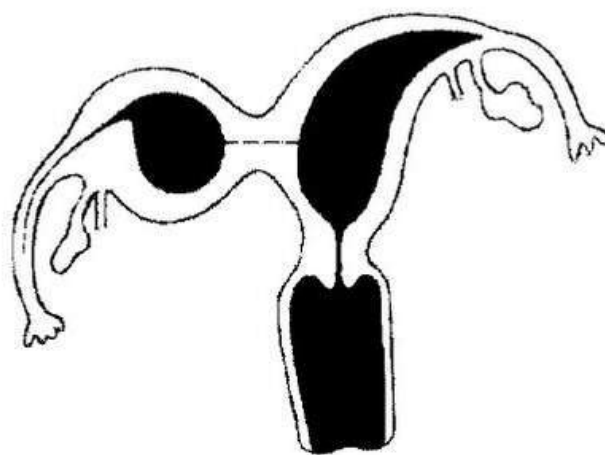


Fig. 43. Uterus bicornis with rudimentary horn

Chapter 10

The operation of Shtrassmann means the opening of the uterus with the help of the transverse section of the area of its fundus with the place of attachment of one salpinx to another with the further connection of horns into the sagittal direction.

The operation of Johnes is comfortable for removal the septum through V-type cut in the area of the uterine fundus.

The operation of Tompkins is as follows: they expose the uterine cavity by the sagittal cut, which occupies two thirds of the anterior and posterior walls of the uterus; then they delete the septum and at last, they connect both halves by two rows of sutures. Before insewing into the uterine cavity the surgeon enters the Lips's loop or the silicon tube to prevent the forming of adhesions.

MALDEVELOPMENT OF UTERINE TUBES

Among maldevelopments of the uterine tubes they distinguish: the involvement of the extraordinarily long tubes into the hernia sack in the inguinal hernia; the uterine tubes of the spiral form; congenital obliteration of the tubes or their fallopian ostia; and also imperforations of the tubes, which clinically signed by sterileness, doubling of tubes, which are usually accompanied by doubling of the ovaries; the presence of additional blind canals, additional openings in the area of the abdominal lumen of the tube, congenital diverticula of the tubes.

MALDEVELOPMENT OF OVARIES

Such types of violation of development of the ovaries are known: *agonadism* can be *true* (aplasia of the ovaries) and *pseudogonadism* (the regressive form); *hypergonadism* can be *true* (hyperplasia) and *pseudohypergonadism* (fibrocystic and polycystic ovaries); *hypogonadism* can be *primary* (hypoplasia of the ovaries) and *secondary* (atrophy); *ambigogonadism* can be one-sided and bilateral. The cause of the primary hypogonadism is anomaly in the chromosomes of the sexual glands; of the secondary is gonadotropic insufficiency of the hypophysis. The complete absence of the ovarian tissues is observed rarely. In such cases in the place of gonads they see the fibrotic bundles. The noted anomaly is characteristic for the different types of gonads' dysgenesis (Turner's syndrome, the pure and mixed forms of gonads' dysgenesis).

The complete absence of the appendages, the paramesonephral ducts and rudiments of the kidneys is marked only in the nonviable fetus. One-sided absence of the appendages, the paramesonephral duct and the kidney on this side, the presence of the unicornous uterus is the extraordinarily rare phenomenon. There are also the additional ovaries, which are formed as a result of separating parts of rudiment of the ovary on the early stages of the embryo development.

INFANTILISM

The sexual infantilism is characterized by the excalation (anatomic and histological) of the genital organs and hypofunction of the ovaries. If the sexual infantilism is combined with general, it can be diagnosed in the age of 13—14 years. The general infantilism is characterized by insufficient expressing of the secondary sexual signs (later aged

development in 1–3 years from normal) and violation of the anthropometric indices. The sexual infantilism is diagnosed in 4–16 % of the inspected girls, in half of which it is combined with the general infantilism.

Etiology

Except of the inherited violations and complicated flow of the intrauterine development, hypovitaminosis in the postnatal period, child's infections, tonsillitis, rheumatism, operations on the ovaries also lead to the appearance and development of the infantilism.

The infantilism causes the hypofunction of the ovaries, inferior cyclic changes of the endometrium and is accompanied by the changes of the thyroid gland's function. The reduced sensitiveness of the ovaries to the gonadotropic hormones is marked in addition, and of the organs-targets (uterus, vagina, breasts) to the steroid hormones. Thus it is observed hyperproduction of FSG and hypoproduction of LG.

The infantilism is also characterized by decline of the contractive ability of the uterus; it is related with the changing of activity of the estrogenic receptors. A rather important role plays violations of innervation, and also the intraorganic and pelvic hemodynamics.

Clinical presentation

The infantile girl is usually not high; she has thin bones; generally-equally-narrowed pelvis; the late menarche; the hypomenstrual syndrome, which is quite often combined with algodysmenorrhea. In the case of the genital infantilism there is disparity between the proportional stature and the exclamation (sometimes expressed) of the genital organs.

For determination of the expressing of the sexual infantilism a considerable role plays the size of the uterus, which is in the state of hypoplasia. There are three degrees of exclamation of the uterus: *the rudimentary (embryonic) uterus, the infantile uterus and the hypoplastic uterus.*

The rudimentary or embryonic uterus is of 1 to 3 cm long, thus the cervix occupies the considerable part. Such variant is met very rarely; it is greatly similar to the maldevelopment of the genital organs, than to the exclamation. The pathology is accompanied by hypoestrogeny and the proof amenorrhea. In some cases the patients complain of the insignificant menstrual-like excretions. The prognosis to renew the specific functions of the female organism is unfavorable.

The infantile uterus has the length over 3 cm. The ratio of the cervix and the uterine body is 3:1, the same as for the girls of the prepubertal age. During the bimanual examination they expose hyperanteflexio of the uterus, weak expressing of the vaginal vaults, and higher location of the ovaries, the long and winding uterine tubes. Menstruations are painful and observed rarely. To renew the reproductive function the protracted therapy is needed.

The hypoplastic uterus is 6–7 cm long, the ratio between the length of the cervix and the uterine body is physiological (1:3). The hypoplastic uterus is formed not only as a result of the negative influences during the antenatal period and in the period of childhood, but also as a result of the carried in the pubertal period the local inflammatory processes. This pathology can disappear by itself after the beginning of the sexual life and pregnancy.

Diagnostics

The diagnostics is based on the data of anamnesis, results of the objective investigations (anthropometry, making morphogrammata, and sounding of the uterus, hysterosalpingographia, determination of the bones' age (in children's practice), laboratory re-

Chapter 10

searches and others). In anamnesis there are quite often points on the unfavorable motion of the antenatal period, and also a lot of infectious and other diseases in childhood. The most typical complaints are the late appearance of menstruation, violation of the menstrual cycle as the hypomenstrual syndrome and usually sickly menstruations. Objectively: the small (rarer high) height; the maldevelopment of the thorax, the breasts, the narrowed pelvis; deficiency of hair in the pubic and armpits' areas. The small pudendal lips are given out forward; the clitoris seems a bit larger because of the hypoplasia of the external genital organs. During the bimanual research they expose the maldeveloped uterus, which is in the state of hyperanteflexio.

In the case of combination of the sexual infantilism with the general maldevelopment they see such the intersexual features as: the enlarged in volume thorax; the decreased in size pelvis (especially the external conjugate); and the lag behind the bone age against the calendar.

The production of the gonadotropic hormones (FSH and LH) has acyclic character, that's why the production of the sexual steroid hormones is limited. The level of 17-ketosteroids meets an aged standard. The content of the sexual chromoplasm and the karyotype are without changes.

Among the modern methods of research the diagnostic value is presented by the hysterosalpingography, USE, dopplerometry, MRT, CTG, which determine the state of the internal ostium of the uterus (dilatation), the cervical canal of the uterus (lengthening with the expressed palm-like folds) and the uterine tubes (length, winding). The lag behind the bones' age against the calendar is set by the method of sciagraphy; it differs in 1–4 years.

The differential diagnostics of infantilism of the genital organs is conducted with the juvenile hypothalamic syndrome, the Shtein-Levental's syndrome, dysgenesis of gonads (pure form) and the congenital endometriosis.

Treatment

The treatment of the infantilism of the genital organs, except of the cases of the expressed exhalation (embryonic uterus), is usually effective and consists of the removal of reasons of the lag behind the development of the genital organs; the creation of 'background of readiness' or the state of the increased sensitiveness of the organs-targets to the action of the sexual hormones; selection of the adequate substitutive therapy on a background of the 2–3-months courses of vitamin therapy (E, C, B₁, B₆) and indicating ATP.

Beginning to use the hormonal therapy, it follows to make sure in absence of the anomalous gonads (pseudomale hermaphroditism, testicular feminisation) and eliminate the hormonal-active tumors of the ovary. During 3–4 months it is recommended to introduce estrogens (Microfollin, Estrophem) and Progesteron (Utrogestan) in the minimal doses cyclically. After the course of the hormonal treatment it is needed to have a break in 3 months. The next course is conducted only in the case, if there was no insufficient effect of the previous course.

They also recommend using the physiotherapy (electrophoresis of *copper* from the 5th to the 13th day of the cycle, and of *zinc* from the 14th to the 24th day), the electroreflexotherapy (acupuncture, electrostimulation of the cervix), medical gymnastics and balneotherapy. In the cases of the mild degree of the infantilism they indicate the application of paraffin, ozocerite and sulfide waters. The mud care and the gynecological massage are widely used too.

CONTENTS

CHAPTER 1. FOUNDATIONS OF GYNECOLOGICAL CARE, FEMALE DEPARTMENT AND GYNECOLOGICAL HOSPITAL	3
Organization of Outpatient Gynecological Care	3
Organization of Gynecological Care in the Hospital	8
CHAPTER 2. ANATOMY AND PHYSIOLOGY OF FEMALE GENITAL ORGANS	10
External genital organs	10
Internal Genital Organs	12
Ligaments of the Internal Genital Organs	17
Blood Supply of the Genital Organs	19
Innervation of the Genital Organs	20
Lymphatic Supply of Genital Organs	20
Age Features of Anatomy and Physiology of the Female Genital Organs	20
Regulation of the Ovarian-Menstrual Cycle	22
Test tasks	23
CHAPTER 3. GENERAL SYMPTOMATOLOGY AND DIAGNOSTICS OF GYNECOLOGICAL DISEASES	25
Main Symptoms of Gynecological Diseases	25
Medical History (Anamnesis)	29
Basic and Special Methods of Examination of the Gynecological Patients	31
Test tasks	46
CHAPTER 4. INFLAMMATORY DISEASES OF THE FEMALE GENITAL ORGANS	49
Etiology and the Ways of Spreading	49
Physiological Barriers, Which Prevent Spreading of the Inflammatory Diseases in Women	49
Classification of the Inflammatory Diseases of the Genitals	50
Inflammatory Diseases of the Lower Genitals with Nonspecific Etiology	51
Inflammatory Diseases of the Upper Genitals	54
Inflammatory Diseases of Genitals with Specific Etiology	60
Test tasks	67
CHAPTER 5. MENSTRUAL DYSFUNCTION AND NEUROENDOCRINE SYNDROMES	69
Etiology of the Menstrual Dysfunction	69
Classification of the Menstrual Dysfunction	70
Amenorrhea and Hypomenstrual Syndrome	71
Dysfunctional Uterine Bleeding	78
Algodismenorrhea	81
Neuroendocrine Syndromes	83
Test tasks	93
CHAPTER 6. GENITAL ENDOMETRIOSIS	96
Epidemiology	96
Etiology and Pathogenesis	96
Classification of the Endometriosis	98
Clinical Presentation of other Forms of Endometriosis	99
Treatment of the endometriosis	106
Test tasks	108
CHAPTER 7. BENIGN TUMORS AND TUMULAR LESIONS OF GENITAL ORGANS	111
Benign Tumors of the External Genital Organs	111
Benign Tumors of the Uterine Body	112
Benign Lesions of the Ovaries	116
Benign Tumors of the Fallopian Tubes	124
Test Tasks	124
CHAPTER 8. PREMALIGNANT AND BACKGROUND LESIONS OF GENITAL ORGANS	128
Premalignant Lesions of the External Genital Organs	128
Premalignant Lesions of the Vagina	130
Premalignant Lesions of the Cervix	130
Hyperplastic Processes of Endometrium	133
Test Tasks	140
CHAPTER 9. MALIGNANT NEOPLASMS OF FEMALE REPRODUCTIVE ORGANS	143
Vulval Cancer	143
Vaginal Cancer	144
Cervical Cancer	146
Endometrial Cancer	148
Uterine Sarcoma	150
Trophoblastic Disease	152
Malignant Tumors of Ovaries	154

Tumors of Fallopian Tubes.....	157
Test Tasks	159
CHAPTER 10. MALDEVELOPMENTS OF FEMALE GENITALIA AND PUBESCENCE DISORDERS	164
Etiology and Pathogenesis	164
Hymen and Vulval Maldevelopments	165
External Genitals Maldevelopments	166
Vaginal Maldevelopments	166
Uterine Maldevelopment	169
Maldevelopment of Uterine Tubes	172
Maldevelopment of Ovaries	172
Infantilism.....	172
Violation of Sexual Development	175
Test Tasks	183
CHAPTER 11. MALPOSITION AND TRAUMATIC INJURIES OF FEMALE GENITALIA	186
Normal (Typical) Position of the Sexual Organs.....	186
Age Peculiarities of the Position of the Female Genital Organs.....	186
Malpositions of the Female Genitalia.....	187
Genital Injuries	200
Test Tasks	206
CHAPTER 12. INFERTILE MARRIAGES AND MODERN REPRODUCTIVE TECHNOLOGIES, CONTRACEPTION	209
Female Infertility	209
Male Infertility.....	219
Morden Reproductive Technologies	220
Contraception	230
Test Tasks	244
CHAPTER 13. GYNECOLOGICAL DISEASES IN CHILDREN AND YOUNG GIRLS	248
Anatomical and Physiological Features of the Girls' Genitals in the Process of Formation of the Reproductive System.....	248
Features of Girls' Examination.....	249
Inflammatory Genital Diseases.....	253
Menstrual Dysfunction	256
Tumors of the Genitals	260
Injuries of the Genitals	263
Test Tasks	264
CHAPTER 14. URGENT STATES IN GYNECOLOGY	266
Ectopic Pregnancy.....	267
Ovarian Apoplexy	277
Torsion of Ovarian Tumor Crus	278
Urgent States in the Leiomyoma of the Uterus.....	279
Pyosalpinx and Pyovar.....	280
Test Tasks	281
CHAPTER 15. TYPICAL SURGICAL INTERVENTIONS AND ENDOSCOPIC SURGERY IN GYNECOLOGY	285
Preoperative Preparation.....	285
The Postoperative Period Treatment	286
Operations on the Vaginal Portion of the Cervix.....	288
Operations in the Case of the Ptosis and Prolapse of the Genitals.....	290
Transabdominal Gynecological Operations on the Appendages and the Uterus.....	291
Small Gynecological Operations.....	294
Endoscopic Surgery (Laparoscopy, Hysteroscopy)	295
Test Tasks	299
CHAPTER 16. DISEASES OF UROGENITAL SYSTEM, GENITAL FISTULAE	302
Urinary Incontinence.....	303
Maldevelopments of the Urinary System.....	307
Traumatic Injuries of the Urinary Organs.....	310
Cystalgia (Cystic Neurosis, Genital-Vesical Disfunction, Unstable Bladder, Urethral Syndrome)	314
Cystitis.....	315
Ligature calculi of the urinary bladder.....	316
Genital Fistulae	316
Test Tasks	320
CHAPTER 17. THE ISSUE OF WOMEN'S SEXOPATHOLOGY	322
Test Tasks	328
APPLICATIONS	331
REFERENCE LIST	349

MEDLIT
медична література

КУПИТИ